

## Hyaluronic Acid Associated with Abobotulinumtoxin Use along the Lower Periorbital Area: A Prospective Study

Denis Souto Valente<sup>1\*</sup>, Rafaela Koehler Zanella<sup>2</sup> and Sibelie Souto Valente<sup>3</sup>

<sup>1</sup>Department of Medicine and Health Sciences, PUCRS School of Medicine (FAMED), Brazil

<sup>2</sup>Dermatologic Surgery Department, Mae de Deus Health System, Rua Soledade, Brazil

<sup>3</sup>Postgraduate Division Professor, Anhanguera Pelotas College, Av Fernando Osório, Brazil

\*Corresponding author: Denis Souto Valente, Department of Medicine and Health Sciences, PUCRS School of Medicine (FAMED), Av Ipiranga 6681, Porto Alegre, RS, ZIP 90619-900, Brazil, Tel:+555130612484; E-mail: [denisvalentedr@gmail.com](mailto:denisvalentedr@gmail.com)

Received date: November 20, 2015; Accepted date: January 11, 2016; Published date: January 15, 2016

Copyright: © 2015 Valente DS. This is an open-access article distributed under the terms of the Creative Commons Attribution License, which permits unrestricted use, distribution, and reproduction in any medium, provided the original author and source are credited.

### Abstract

**Objective:** The aim of this study was to describe the superficial layer technique for filling the lower periorbital area (LPOA) using injectable Hyaluronic Acid (HA) associated with Botulinum Toxin (BTX) injections on the same procedure, as well as presents its safety and effectiveness.

**Methods:** HA was applied above the orbital muscle starting from the infraorbital edge at the tear groove region going cranially to the edge of the lower eyelid with slow and steady movements. Then 45 Speywood Units of the BTX solution was injected in three equally divided doses along the lateral orbital rim in each side. The evaluation was performed by two independent physicians comparing before and 2 months post-procedure pictures giving scores ranging from none improvement (0) to maximum improvement (100). The intervention results were also measured by patients along the 2 months revision with a visual analogue scale using a 10 cm ruler where the score was determined by calculating the distance in mm from 0 to the patient's mark along the 10 cm line between the "none improvement" and the "maximum improvement" anchors providing scores from 0 to 100.

**Results:** 42 individuals entered the study. The evaluation conducted by the independent physicians showed an 84.1% improvement mean. Regarding patient satisfaction 0% found no improvement, 4.8% mild improvement, 26.3% moderate improvement, 64.1% great improvement and 4.8% maximum improvement after the procedure.

**Conclusion:** The AH and BTX use along the LPOA has proven to be a safe procedure. Therefore our data suggest that this technique is easy to perform, presents low risk of complications and provides a high degree of satisfaction among patients and independent evaluators.

**Keywords:** Soft tissue augmentation; Mesotherapy; Dermal fillers; Hyaluronic acid; Botulinum toxin; Facial rejuvenation; Blepharoplasty

### Introduction

The search for the correction of facial aging signs has stimulated the development of new non-surgical treatments. Special attention has been given to the lower periorbital area (LPOA), where multifactorial changes are responsible for skin aging. Several surgical and non-surgical procedures have been described to correct or minimize these changes including volume restoration using dermal fillers and chemical denervation using botulinum toxin (BTX) [1-3].

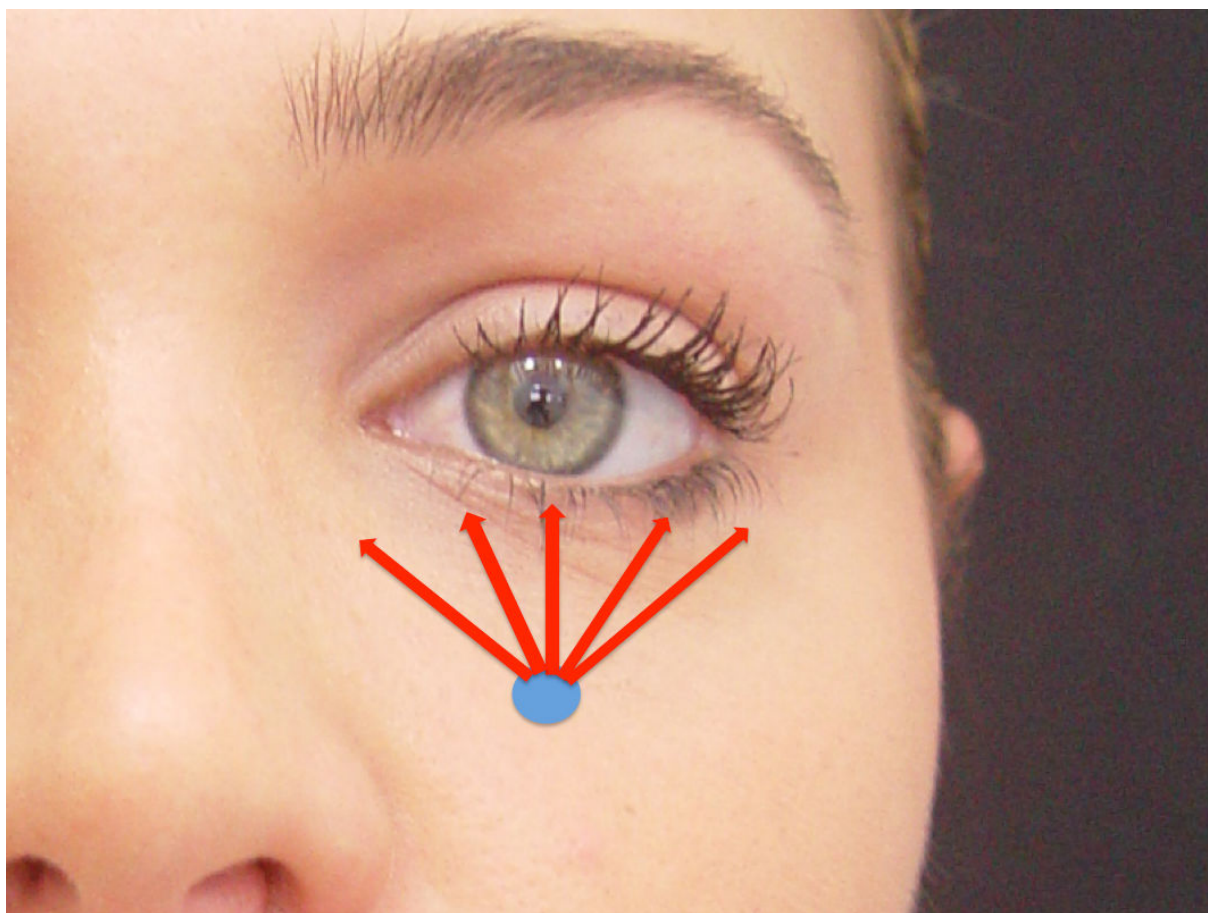
Currently, hyaluronic acid (HA) is the safest and most widely used injectable dermal filler. Rarely induces serious adverse effects, and most of its complications disappears when the product is degraded. LPOA can be a challenging site for facial rejuvenation. In an attempt to improve the aesthetics of this area several authors propose treatments using HA injection and BTX [4-6]. The aim of this study was to describe the superficial layer technique for filling the LPOA using AH associated with BTX on the same procedure, as well as present its safety and effectiveness.

### Materials and Methods

This prospective study was conducted in a private clinic from July 2014 to August 2015. The patients were photographed before and 60 days after the procedure. The evaluation was made by two independent physicians: a dermatologist and a plastic surgeon comparing before and 2 months post-procedure digital photographs giving scores ranging from none improvement (0) to maximum improvement (100). The intervention results were also measured by patients along the 2 months revision visit with a visual analogue scale (VAS). Using a 10 cm ruler where the score was determined by calculating the distance in mm from 0 to the patient's mark along the 10 cm line between the "none improvement" and the "maximum improvement" anchors providing a range of scores from 0 to 100. A higher score indicates greater enhancement. Based on the distribution of VAS scores the following cut points regarding improvement have been used: no improvement (0 mm to 10 mm), mild improvement (11 mm to 40 mm), moderate improvement (41 mm to 70 mm), great improvement (71 mm-89 mm) and maximum improvement (90 mm-100 mm). Ending the data collection, the results were presented and analysed with descriptive statistics using SPSS-18 (IBM, USA) software.

Procedural technique: topical anaesthesia with Pliaglis (G Production, Canada) was performed 20 minutes prior the procedure and chlorhexidine gluconate 2% was applied. The patients were positioned in a 45° inclination to the vertical axis and were instructed to look to their own eyebrows in order to highlight the palpebromalar fat compartments. Restylane Vital (QMed AB, Sweden) was applied above the orbital muscle starting from the infraorbital edge at the tear

groove region going cranially to the edge of the lower eyelid with slow and steady movements. The product was introduced by retro injection in the subdermal layer, with a fan pattern from the mediopupillar sagittal line at the orbital rim, Figure 1 shows the distribution technique. The HA is then moulded and distributed with gently finger pressure for better dispersion of the product and to avoid overcorrection.



**Figure 1:** HA schematic distribution.

2 mL of non-preserved 9 mL/L sodium chloride was added in a vial of 300 U Dysport (Ipsen Biopharm Ltd, United Kingdom). Then 0.3 mL (45 Speywood Units) of the solution was injected in three equally divided doses along the lateral orbital rim in each side, Figure 2 shows the more often used sites of injection.

Cold compresses were applied immediately after the procedure to prevent swelling and bruising and the patients were instructed to avoid physical exercise, local massage and high temperatures exposure during the following 48 hours. The patients were all photographed and analysed under standard conditions before treatment and two months after its realization. Additional treatments such as laser or chemical peels were not permitted in these patients in the following two months. Patients were evaluated at 15 days and two months after the procedure in order to observe possible adverse effects.

### Ethics Statement

All participants were made aware of the study and provided written and informed consent prior to study initiation and patient enrolment. This study is in accordance with the 2000 Edinburgh, Scotland Revision of the Declaration of Helsinki, applicable ICH guidelines, and Guidelines on Research Practice. This study did not affect the medical assistance provided to the patients. All participants provided written consent before the procedure, so that their data, as well as before and after images, could be used in this research.

### Results

42 individuals entered the study. 40 were female (95.2%), and the average age was 36.8 years, their characteristics can be observed along Table 1.

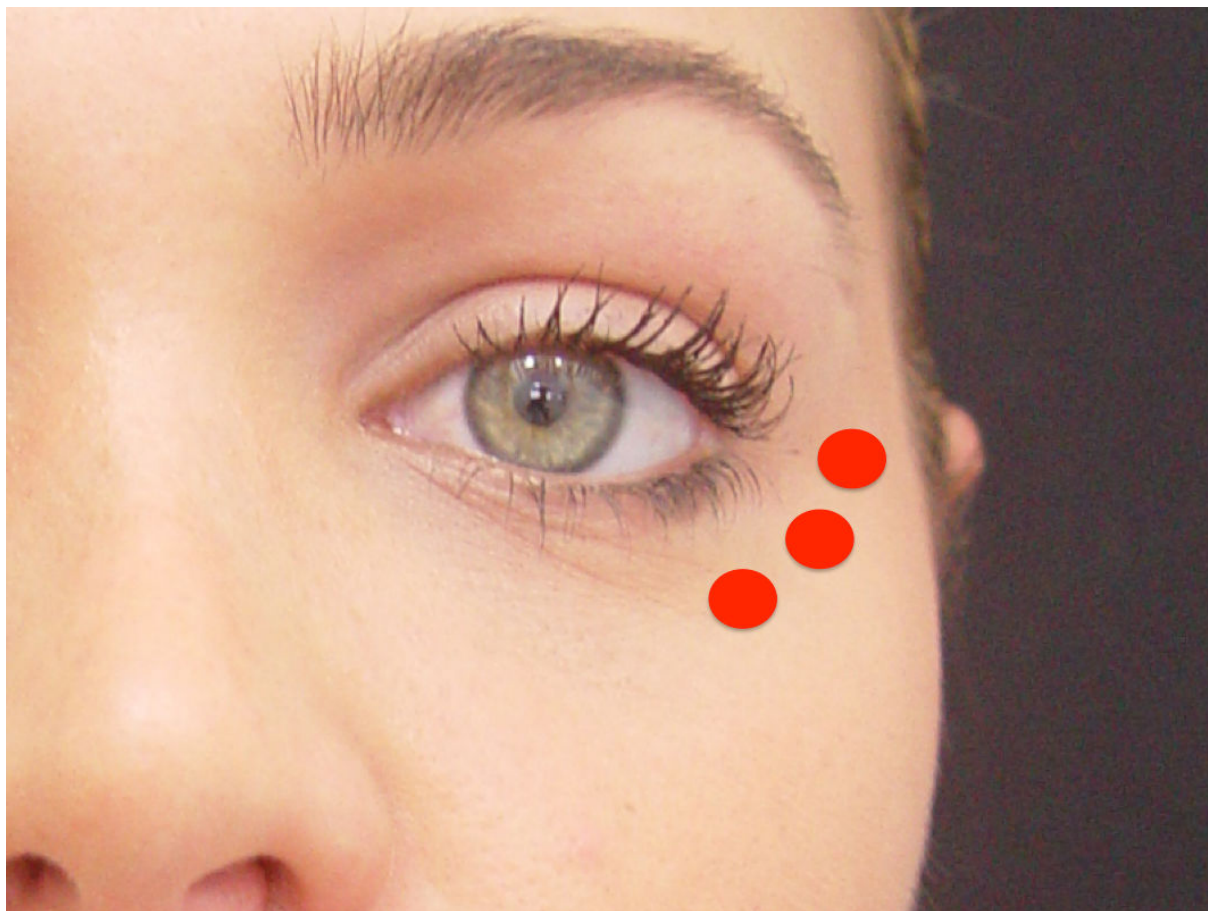


Figure 2: BTX schematic distribution.

	Mean
Age (years)	36.8
Caucasian (%)	100
BMI (kg/m <sup>2</sup> )	22.3
Smoking (%)	9.6
Postprocedure evaluation (days)	62.1

Table 1: Sample characteristics.

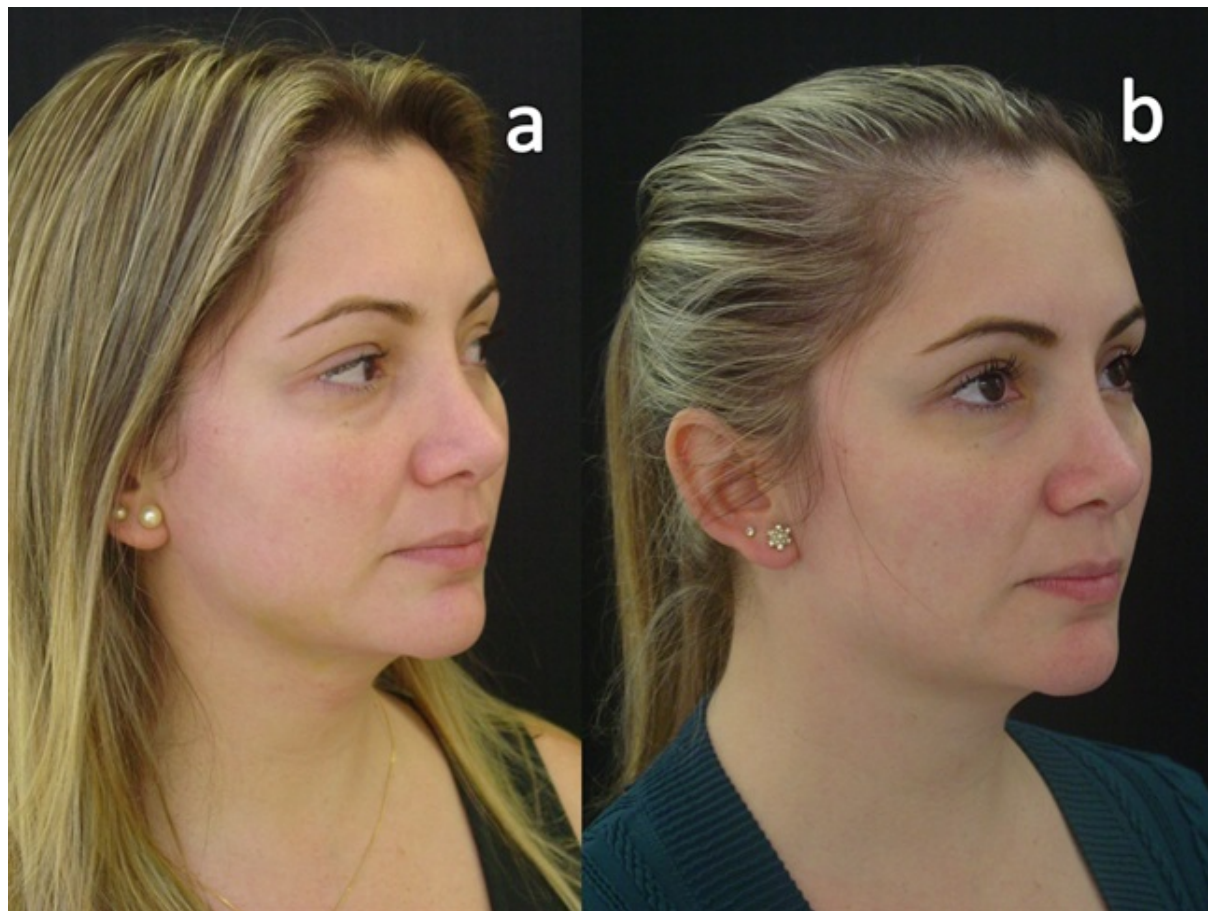The results presented here were observed after a single application. The volume of HA injected varied from 0.3 mL to 0.5 mL per side with a 0.39 mL mean, and each patient received 90 Speywood Units of BTX.

The evaluation conducted by the independent physicians showed an 84.1 improvement mean. Regarding patient satisfaction 0% found no improvement, 4.8% mild improvement, 26.3% moderate improvement, 64.1% great improvement and 4.8% maximum improvement after the procedure. Figure 3 shows a comparison of the obtained results.

Two individuals complained of mild and transient ecchymosis. In two cases there were an irregularity in cutaneous surface filled area (overcorrection), requiring local treatment with hyaluronidase 1000 RTU. All individuals were able to return to their activities on the day following the procedure. None of the patients complained of nodules, lumps, pain, Tyndall effect or skin colour changes during the studied follow up.

## Discussion

Several techniques are described for LPOA treatment. Some articles report the use of fillers, and discuss which filler would be more appropriate, because in this region the skin is very tenuous and vascularized. Among them, HA is presented as the most suitable for its simplicity in application, its low allergenic potential and its homogeneous texture providing predictable aesthetic results with low complications risk when applied in the skin layer. Restylane Vital is a form of stabilized non-animal HA for skin rejuvenation. This product is intended to improve the elasticity of the skin, restore its hydrobalance, and meliorate the skin structure [7-9].



**Figure 3:** 32 year's old female (a) before the procedure; (b) 2 months after.

The LPOA has an extremely thin dermis, composed of loose connective tissue virtually absent in the pre-tarsal and medial and lateral ligaments of the eyelid, where it adheres to the fibrous underlying tissue. Due to the peculiar anatomy of LPOA there is no consensus in the literature regarding the best technique for HA application. Special attention should be taken to avoid an injection through the orbital septum. Its laceration can cause intraorbital fat herniation or an inadvertent injection at the extraocular muscles. In cases of immediate hematoma, the procedure must be interrupted in order to minimize the risk of vascular embolism. It is necessary to apply the HA relatively quickly avoiding that the oedema caused by its injection distorts the local anatomy [10-12]. The technique here described allows a continuous visualization of the needle to assert that the correct layer receives the HA.

As stated by Landau and Fagien [13] “the first product designed specifically for skin-boosting purposes was Restylane Vital. The product comprises small particles stabilized smooth and relatively thin NASHA gel (20 mg/mL). The investigators found that micropuncture injections of Restylane Vital significantly increased skin elasticity and created positive impact on skin surface roughness. Boosting of facial skin through fibroblast activation is a new indication for HA-based products. Injectable HA has also been recently registered in Europe as agents specific for the improvement of skin quality (Restylane Skinboosters). The procedure hydrates the dermis and creates stable

extracellular matrix to support intradermal fibroblasts structure that is essential for their normal function”. For those reasons we choose Restylane Vital to our study.

In addition to being biocompatible, easy to store and not immunogenic, HA offers a great advantage over all other cutaneous fillers: solubility in hyaluronidase. This property allows the correction of excessive injections and the total removal of the product in case of chronic adverse reaction. Only one patient required hyaluronidase for irregularity correction after the procedure. Other complications described, but not found in this study were: lymphedema unresponsive to hyaluronidase, persistent erythema, migraine and local cellulitis. Another complication described, and fortunately rare, is blindness. To avoid the ophthalmic artery embolization some precautions are described, among them to abstain applications near the inner corner of the eye in order to avert the Angular arteries, apply small amounts of filler, inject slowly, preclude the bolus technique and microcannulas with blunt tip use [14-17].

The lateral portion of the orbicularis oculi muscle is the target of the BTX technique here presented. When this portion gets paralyzed the skin of the LPOA become looser allowing a better accommodation of the HA. This muscle portion also acts as an accessory upper cheek elevator. A side effect sometimes observed is a small loss of upper cheek elevation [18]. In our study templates of BTX injection points

were not used because, depending on where the muscle wrinkling the skin is strongest, injections sites should be individualized in each patient.

Most studies use subjective evaluation methods to assess cosmetic outcomes. The VAS scale is an objective method that must be shown to the patient otherwise it would be an auditory scale instead of a visual one. Its use estimates a difficult to measure dimension comprising patients' expectations and obtained results. It was used in our study to have a numeric transformation of the patient's self-perception after the procedure. With this strategy we can provide a validated method for the treatment assessment [19].

In cases with important skin sagging, the traditional blepharoplasty is indicated for tissue removal and correction of the orbital septum. The dermal fillers use can be an ancillary procedure, suitable only for correcting the loss of local volume in these patients.

Our study results interpretation is limited by the lack of a control group. We studied a self-selected group soothing treatment for LPOA. It is clear that it would be difficult to recruit volunteers for a randomized placebo-controlled trial. Despite that, a classical study by Wang et al. [20] can help us. In their manuscript photo damaged forearm skin were injected either with HA (Restylane) or saline solution (Restylane vehicle). HA, but not saline injections, was related with Type 1 collagen deposition around the injection site. Although both studies are not strictly comparable, there is not a reason to believe that LPOA skin would respond contrariwise from forearm skin, assuming this possibility the placebo-controlled trial provides strong evidence that HA could be responsible for some important dermal changes.

In theory, HA is resorbed twelve months after its application. However, clinical observations have been showed the presence of some residual volume effect remaining for more than one year. The action mechanism by which HA promotes the increased volume effect involves the attraction of water molecules into the extracellular matrix. It stimulates the neocollagenesis process improving the dermis elasticity. This study was not designed to assess the effect continuance; in the future we intend to use the same database to assert the outcome duration.

## Conclusion

The HA and BTX use along the LPOA has proven to be a safe procedure. Therefore our data suggest that this technique is easy to perform, presents low risk of complications and provides a high degree of satisfaction among patients and independent evaluators. It is mainly indicated for young patients with no sagging skin.

## References

1. Kane MA, Cox SE, Jones D, Lei X, Gallagher CJ (2015) Heterogeneity of crow's feet line patterns in clinical trial subjects. *Dermatol Surg* 41: 447-456.
2. Carruthers J, Carruthers A (2014) Social significance of the eyebrows and periorbital complex. *J Drugs Dermatol* 13: s7-s11.
3. Pilkington SJ, Belden S, Miller RA (2015) The Tricky Tear Trough: A Review of Topical Cosmeceuticals for Periorbital Skin Rejuvenation. *J Clin Aesthet Dermatol* 8: 39-47.
4. Hamman MS, Goldman MB, Fabi SG (2012) Comparison of two techniques using hyaluronic acid to correct the tear trough deformity. *J Drugs Dermatol* 11: e80-e84.
5. Huber-Vorländer J, Kürten M (2015) Correction of tear trough deformity with a cohesive polydensified matrix hyaluronic acid: a case series. *Clinical, Cosmetic and Investigational Dermatology* 8: 307-312.
6. Brin MF, Boodhoo TI, Pogoda JM, James LM, Demos G, et al. (2009) Safety and tolerability of onabotulinumtoxinA in the treatment of facial lines: a meta-analysis of individual patient data from global clinical registration studies in 1678 participants. *J Am Acad Dermatol* 61: 961-970.e1-11.
7. Cohen JL, Dayan SH, Brandt FS, Nelson DB, Axford-Gatley RA, et al. (2013) Systematic review of clinical trials of small- and large-gel-particle hyaluronic acid injectable fillers for aesthetic soft tissue augmentation. *Dermatol Surg* 39: 205-231.
8. Raspaldo H, Gassia V, Niforos FR, Michaud T (2012) Global, 3-dimensional approach to natural rejuvenation: part 1 - recommendations for volume restoration and the periocular area. *J Cosmet Dermatol* 11: 279-289.
9. Lee S, Yen MT (2013) Injectable hyaluronic acid fillers for periorbital rejuvenation. *Int Ophthalmol Clin* 53: 1-9.
10. Sharad J (2012) Dermal Fillers for the Treatment of Tear Trough Deformity: A Review of Anatomy, Treatment Techniques, and their Outcomes. *J Cutan Aesthet Surg* 5: 229-238.
11. Berros P, Lax L, Bétis F (2015) Hyalurostructure treatment: superior clinical outcome through a new protocol-a 4-year comparative study of two methods for tear trough treatment. *Surg Clin North Am* 23: 257-268.
12. Bravo BSF, Rocha CRMD, Bastos JTD, Silva PMC (2015) Comprehensive Treatment of Periorbital Region with Hyaluronic Acid. *The Journal of Clinical and Aesthetic Dermatology* 8: 30-35.
13. Landau M, Fagien S (2015) Science of Hyaluronic Acid Beyond Filling: Fibroblasts and Their Response to the Extracellular Matrix. *Plast Reconstr Surg* 136: 188S-95S.
14. Valente DS, Zanella RK (2015) Fillers complications for HIV/AIDS lipoatrophy treatment. *Rev. Bras. Cir. Plást* 30: 335-336.
15. Nácúl AM, Valente DS (2009) Complications after polymethylmethacrylate injections. *Plast Reconstr Surg* 124: 342-343.
16. Belezny K, Carruthers JD, Humphrey S, Jones D (2015) Avoiding and Treating Blindness From Fillers: A Review of the World Literature. *Dermatol Surg* 41: 1097-1117.
17. Woodward J, Khan T, Martin J (2015) Facial Filler Complications. *Facial Plast Surg Clin North Am* 23: 447-458.
18. Kane MA (2003) Classification of crow's feet patterns among Caucasian women: the key to individualizing treatment. *Plast Reconstr Surg* 112: 33S-39S.
19. Ferreira MC (2000) Evaluation of results in aesthetic plastic surgery: preliminary observations on mammoplasty. *Plast Reconstr Surg* 106: 1630-1635.
20. Wang F, Garza LA, Kang S, Varani J, Orringer JS, et al. (2007) In vivo stimulation of de novo collagen production caused by cross-linked hyaluronic acid dermal filler injections in photodamaged human skin. *Arch Dermatol* 143: 155-163.